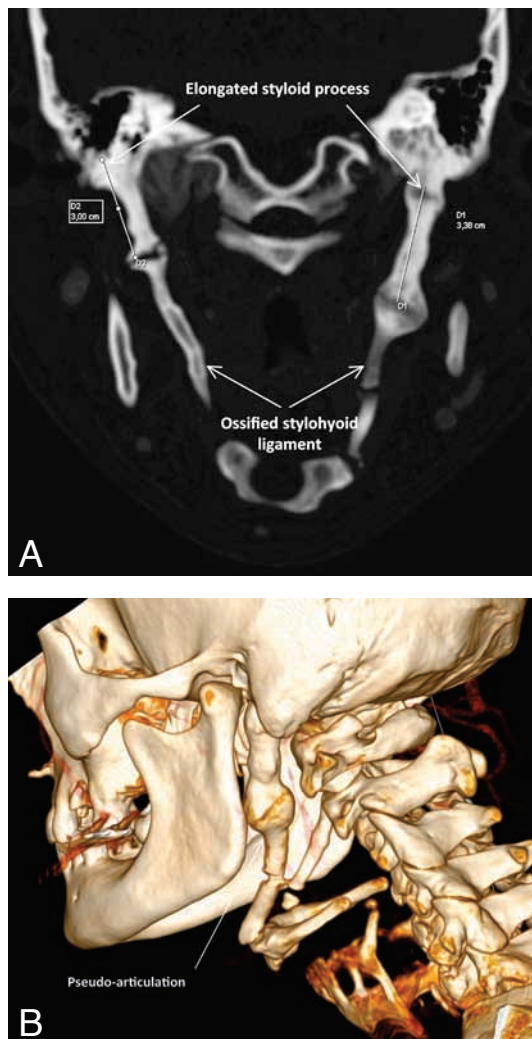


IMAGES IN CLINICAL RADIOLOGY



Eagle syndrome

M. Demeter, Y. De Bruecker, S. Devuyssere, D. Perdieus¹

A thirty-eight-year-old male patient was referred by the general practitioner to our department for recurrent throat pain radiating to head and neck for a few months. The pain was more prominent on the left side, especially during swallowing, and sometimes accompanied by a creaking noise and sensation of a 'click'. Physical examination showed a slightly hard bulge on the left upper neck. Previous medical history was not helpful and laboratory findings were normal. Ultrasound of the neck, as a first investigation, showed no abnormalities. In addition, enhanced computed tomography of the neck was performed. Coronal reconstruction, as shown in Fig. A, revealed total ossification of the stylohyoid ligaments, from the origin on the styloid process to the insertion on the lesser horn of the hyoid bone, as well as enlargement of both styloid processes, more pronounced on the left. Pseudo-articulation between the left stylohyoid ligament and styloid process, also shown in Fig. A and more in detail on the three-dimensional reconstruction in Fig. B, caused the local swelling in the left upper neck. These radiographic findings accompanied by the patient's complaints, is known as "Eagle Syndrome". Because of the minor clinical repercussions, conservative treatment was optioned.

Comment

"Eagle Syndrome" was first described by Eagle in 1937. It is a clinical condition caused by elongation of the styloid process (more than three centimeters in length) and/or ossification of the stylohyoid ligament. It can present unilateral or bilateral. The pathogenesis remains not well known and many pathophysiological explanations are suggested. It can be idiopathic, congenital (due to the persistence of cartilaginous precursors of the styloid process), or acquired, for example after trauma or surgery (due to the proliferation of osseous tissue at the insertion of the stylohyoid ligament). Eagle syndrome can be classified in three types based on the medical history and pathological findings. The first type, known as the classical Eagle syndrome, implies an elongated styloid process with neck surgery (tonsillectomy) or trauma in the

patient's history. In the second type, an elongated styloid process and ossified stylohyoid ligament is seen, without prior surgery or trauma, similar to our case. The third type, or pseudostylohyoid syndrome, contains only the classical symptoms and no clinical or radiographic abnormalities nor prior history. As regards the clinical repercussions, Eagle syndrome can be divided in two main clinical presentations. Our patient presented with the classic stylohyoid syndrome, in the form of cervicofacial pain, dysphagia and foreign body sensation, caused by impingement of lower cranial nerves (V, VII, IX, or X). The second presentation, stylocarotid syndrome, is due to compression of the carotid artery, associated with referred pain, neurological focus and even syncope, mostly induced by head movements. If this is the case, complications are reported, such as (pseudo-)aneurysm and even dissection of the carotic artery, as a consequence of the repetitive traumatic injury of the vessel wall caused by the elongated styloid process or the sharp ends of a partially ossified stylohyoid ligament. Treatment can be conservative with analgetics and steroid injections. In case of neurological deficits, surgical resection of the styloid process by transpharyngeal or more obvious extraoral approach, can lead to complete resolution of the symptoms. 3D-CT scan is certainly of added value, not only for diagnostic purposes, but also in pre-surgical evaluation.

Reference

1. Murtagh R.D., Caracciolo J.T., Fernandez G.: CT findings associated with eagle syndrome. *AJNeuroradiol*, 2001, 22: 1401-1402.

1. Department of Radiology, Imelda Hospital, Bonheiden, Belgium.