

PERCUTANEOUS CHOLECYSTOSTOMY: SINGLE CENTRE EXPERIENCE IN 111 PATIENTS WITH AN ACUTE CHOLECYSTITIS

R. Peters¹, S. Kolderman², B. Peters³, M. Simoens⁴, S. Braak¹

Purpose: To evaluate the safety and long-term outcome of percutaneous cholecystostomy (PC) under radiologic guidance for acute calculous cholecystitis (ACC) and acute acalculous cholecystitis (AAC) in all patients undergoing that procedure at our institution.

Materials and methods: We performed a retrospective analysis of 111 patients who underwent PC from 2004 to 2012. Patients were divided into two groups: AAC and ACC. For all patients, comorbidity and American Society of Anesthesiologists (ASA) classification were determined. The indications, complications, recurrence rate and long-term outcome for both groups were analysed. The mean follow-up was 55 months.

Results: Twenty-four patients with AAC and 87 patients with ACC underwent PC. The most common sonographic findings of ACC and AAC were gallbladder wall thickening (90,9%) and hydrops (72,9%). Twelve of 24 patients with AAC (50%) were hospitalized at the Intensive Care Unit (ICU). Overall, the procedure failed in 2 (1,8%) patients. There were 4 (3,6%) abscesses and 2 (1,8%) fistulas post PC. Drain dislodgment was found without sequelae in 8 (7,2%) patients. Elective cholecystectomy was performed in 35/111 (31,5%). Fifty-one of 87 (58,6%) patients with gallstones underwent cholecystectomy; 36/87 (41,3%) did not undergo surgery due to a too short follow-up or death of non-biliary disease. In the AAC group, there was no recurrent cholecystitis in 17/24 (70,8%) patients; 3/24 (12,5%) underwent surgery and 4/24 (16,6%) patients died in the ICU.

Conclusion: PC is a minimally invasive treatment with low complication rate for patients with acute cholecystitis whom considered being at high-risk for urgent cholecystectomy. Good selection (ASA III and IV) and indication is needed in patients with ACC before PC because the majority will be operated later on. AAC can be managed non-operatively and further treatment might not be needed.

Key-words: Gallbladder, interventional procedure – Cholecystitis.

Acute cholecystitis is a common cause of presentation at the emergency department. Acute inflammation of the gallbladder occurs mostly from persistent obstruction of the cystic duct or gallbladder neck by an impacted gallstone. In the minority of cases (5-10%), acute cholecystitis develops in a gallbladder without gallstones called AAC (1). AAC mainly occurs in seriously ill patients in the ICU or those who have recently undergone the stress of severe trauma or major surgery (2). The etiology is multifactorial and includes ischemia, gallbladder wall infection, chemical toxicity and cystic duct obstruction.

Sonography is the preferred imaging modality for the initial evaluation of patients with suspected acute cholecystitis (1). False-positive results occur in the setting of gallbladder wall thickening in the absence of acute inflammation. Cirrhosis, congestive heart failure, ascites, hepatitis, gallbladder torsion or carcinoma can cause gallbladder wall thickening (3). Rarely, emphysematous cholecystitis is seen in patients with

diabetes in whom foci of gas are identified within the wall and / or lumen of the gallbladder (4).

Surgery is the treatment of choice for acute cholecystitis and is typically performed at presentation if the duration of symptoms is less than 72 hours (5). There is a significant risk of increased operating time, higher conversion rate, more post-operative complications and mortality form urgent cholecystectomy in certain subgroups of patients such as the critically ill patient with comorbidity and in advanced stages of cholecystitis (15). Here, surgery can result in serious complications and even mortality. The mortality in low-risk elderly patients is around 10%, but is as high as 46% in high-risk elderly patients (6, 7, 8). PC can be an alternative treatment in high risk patients. It allows immediate decompression of the acutely inflamed gallbladder (9, 10, 11).

In our hospital, we regard PC as a useful treatment option for patients with high-risk or who present later than 72 hours and still have signs of hydropic, inflamed gallbladder on

ultrasound. The aim of this study was to evaluate the safety success rate, ratio of delayed surgery, complications and clinical outcome of PC under radiologic guidance for ACC and AAC in all patients undergoing that procedure at our institution.

Materials and methods

We reviewed the medical records of 111 patients with acute cholecystitis who underwent PC in the Department of Radiology at Ziekenhuisgroep Twente (ZGT) Almelo/Hengelo in the Netherlands from January 2004 to January 2012. In all cases the diagnosis of acute cholecystitis was made based on clinical signs, laboratories and ultrasonography confirmation. Information entered included patient demographics, sonographic appearance, success rate of PC, drain dislodgement, complications and outcome. Patients were divided into two groups: AAC and ACC. All procedures were performed with ultrasound guidance by Seldinger technique. The gall bladder was visualized and local anesthetic infiltrated into the subcutaneous tissue. In all cases locking pigtail catheters (8.5-French Dawson-Mueller, Cook) were placed into the gallbladder using the free-hand trocar technique. A transhepatic approach, defined as the catheter tract traversing the liver parenchyma, was attempted when possible. Technical success was

From: 1. Department of Radiology, ZGT, Almelo, The Netherlands, 2. Department of Radiology, UMCG, Groningen, The Netherlands, 3. Department of Internal Medicine, AZ Monica, Antwerpen, Belgium, 4. Department of Surgery, ZGT Almelo, The Netherlands.

Address for correspondence: Dr R. Peters, M.D., Department of Radiology, ZGT, Zilvermeeuw 1, 7609 PP Almelo, The Netherlands. E-mail: r_peters86@hotmail.com

defined as placement of a pigtail catheter into the lumen of the gallbladder with aspiration of bile. The mean follow-up was 55 months.

Patients

A total of 111 patients were included (Table I). There were 93 patients with acute cholecystitis presenting at the emergency department and 18 hospitalized patients. Twelve of 18 inpatients were hospitalized at the ICU. There were 58 males and 53 females included with a median age of 72 years (range 25-93 years).

Co-morbidity and American Society of Anesthesiologists (ASA) classification

Most patients had significant associated conditions as listed in Table II. Diabetes, cardiac or renal failure were the most frequent co-morbidities in 88 of 111 patients with acute cholecystitis undergoing PC. Pulmonary co-morbidities were mostly COPD related. Nine patients had a history of terminal malignancy and two polytrauma patients were hospitalized at the ICU.

The American Society of Anaesthesiologists' (ASA) classification was used as grading system for pre-operative health of the patients. Patients of the ASA II group (9%) (primarily operable) had symptoms of cholecystitis occurring longer than 72 hours. Patients with severe systemic disease were 91% (ASA III and ASA IV) of the population (Table III).

Sonographic appearance of acute cholecystitis

Eighty-seven (78%) patients had calculous and 24 (22%) had acalculous cholecystitis (Table V). 87 patients presented with gallstones and in 24 cases there were no gallstones found. 81/111 (72,9%) patients with ACC presented at the Emergency Department. Twelve of 24 patients with AAC even presented with 91,6% and 95,6% respectively. The sonographic Murphy's sign was positive in 50/111 (45,0%) patients (Fig. 1). Eight patients presented with perforation and abscess. Gas was present in 5 (4,5%) patients. A diagnostic CT was indicated for each complicated cholecystitis.

The most common sonographic finding of ACC and AAC was gallbladder wall thickening (90,9%) and hydrops (72,9%) (Table IV). Patients with AAC even presented with 91,6% and 95,6% respectively. The sonographic Murphy's sign was positive in 50/111 (45,0%) patients (Fig. 1). Eight patients presented with perforation and abscess. Gas was present in 5 (4,5%) patients. A diagnostic CT was indicated for each complicated cholecystitis.

Table I. — Age and gender distribution of patients with acute cholecystitis.

Demography			
	Men	Women	Overall
Age			
Mean	72.6	71,5	72,1
Range	35-93	25-92	25-93
Inpatients	12	6	18
ED	42	51	93
Total	58	53	111

Table II. — Comorbidities in 91 of 111 patients.

Co-morbidities	
Cardiac failure	62
Diabetes mellitus and renal failure	26
Pulmonary	18
CVA	10
Malignancy	9
Polytrauma	2

Table III. — ASA classifications of the patient population.

ASA-classification	
ASA II	9%
ASA III	62%
ASA IV	29%

Follow-up

In 109/111 (98,2%) the placement of PC was successful. The cholecystostomy tube procedure failed in 2 (1,8%) patients because of pain and vasovagal reaction. The findings for complications were as follows: there were no procedure-related deaths, there were 4 (3,6%) abscesses and 2 (1,8%) fistulas post PC. Drain dislodgment was found without sequelae in 8 (7,2%) patients (Table VI). Twenty-four patients with AAC and 87 patients with ACC underwent PC. The mean follow-up was 55 months. In the AAC group, seventeen of 24 (70,8%) patients healed with PC and antibiotic treatment. None of these patients needed surgery in the follow-up period, so there was no recurrent cholecystitis. There were 2 patients of the AAC group who underwent emergency cholecystectomy and 1 elective surgery because the patient took the drain out. 4 patients died of other causes with their catheters in situ at the ICU. Fifty-one of 87 (58,6%) patients with gallstones underwent cholecystectomy at a later date; 34 (39%) patients recovered from the acute illness and underwent

elective cholecystectomy. 17 (19,5%) patients needed an emergency cholecystectomy because of recurrent cholecystitis. 19/87 (21,8%) did not undergo surgery and there was no recurrent cholecystitis in the follow-up period. 17/87 (19,5%) died of non-biliary cause mostly elderly patients with severe incurrent illnesses (Fig. 2).

Overall, in 35/111 (31,5%) patients, PC was performed as a temporising measure, with final elective cholecystectomy at a later date. There were 36/111 (32,4%) patients presented with acute cholecystitis who had no recurrent cholecystitis. Nineteen (19/111) patients needed emergency cholecystectomy (Table VI).

Discussion

Sonography is the imaging modality of choice for the initial evaluation of patients with suspected acute cholecystitis. Most sonographic findings are non-specific but are suggestive for acute cholecystitis (1, 3). It is important to demonstrate gallstones in the gallbladder. Ultrasound can detect stones and has a sensitivity of approximately 95% and a specificity

Table IV. – Sonographic findings.

	CALCULOUS (n = 87)	ACALCULOUS (n = 24)	TOTAAL (n = 111)
Gallbladder wall thickening	79 (90,8%)	22 (91,6%)	101 (90,9%)
Hydrops	58 (66,6%)	23 (95,6%)	81 (72,9%)
Murphy's sign	35 (40,2%)	15 (62,5%)	50 (45,0%)
Sludge	35 (40,2%)	12 (50%)	47 (42,3%)
Pericholecystic fluid	21 (24,1%)	9 (37,5%)	30 (27%)
Perforation	7 (8,0%)	1 (4,1%)	8 (7,2%)
Abscess	7 (8,0%)	1 (4,1%)	8 (7,2%)
Gas	3 (3,4%)	2 (8,3%)	5 (4,5%)

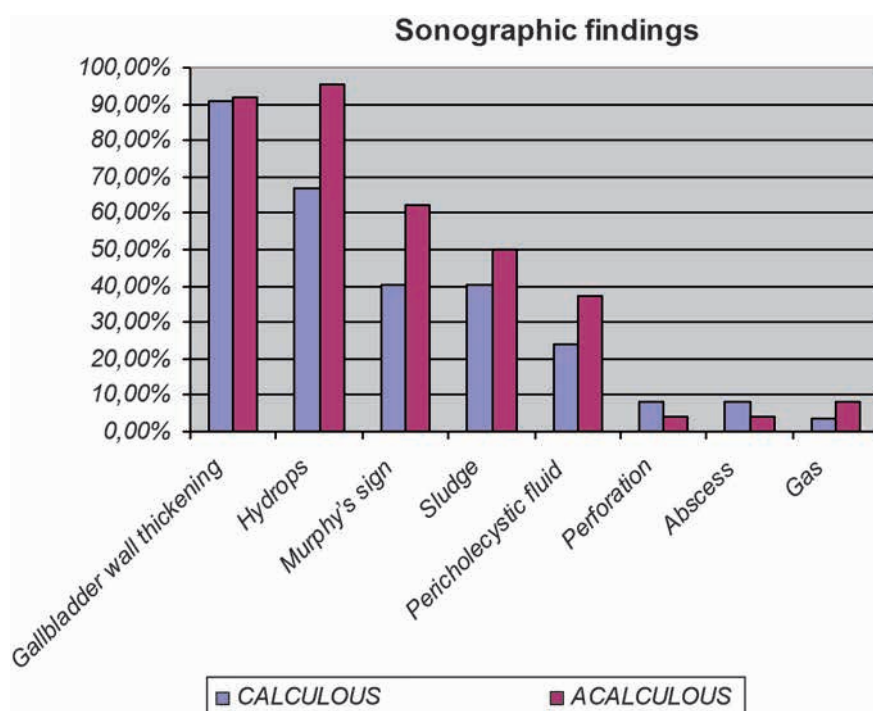


Fig. 1. – Sonographic findings

Table V. – Acute calculous and acalculous cholecystitis.

	Calculous	Acalculous	Overall
Inpatients	3	3	6
ED	81	12	93
IC	3	9	12
Totaal	87	24	111

of appr. 97% (12). In our study, gallbladder wall thickening and hydrops are the most common sonographic appearance for ACC and AAC. Murphy sign was in 45% positive but we believe our patient group – mostly elders and IC patients – were less reliable for pain stimulus. ACC is more common in patients with acute cholecystitis diagnosed at the ED, whereas AAC is mainly found in the

critically ill, already hospitalised patient. Ultrasonography remains operator dependent.

In this study PC was performed for critically ill patients who are not acceptable candidates for emergency surgery because of severe comorbidities and in advanced stages of cholecystitis. The general medical condition of our PC patients is a reflection of the older age and a high

prevalence of comorbidities, so these patients are categorised with a high ASA classification. In the present series, the minority group were ASA II patients (9%) who have been symptomatic for more than 72 hours and the surgery decided not to operate. 91% of our 111 patients were classified as ASA III and IV. ASA III and IV patients have a too high surgical or anaesthetic risk for urgent cholecystectomy.

Tube cholecystostomy is a procedure to decompress the acutely inflamed gallbladder. Successful drainage by PC was achieved in 98,2% of the patients. The procedure failed in 2 patients because of pain and vasovagal reaction. This result is consistent with the literature (13). So, the technical success rate is very high in experienced hands. The access route can be either transperitoneal (TP) or transhepatic (TH). In all patients, PC was performed under local anaesthesia with ultrasound guidance. Unfortunately, in our data there was a lack of description of the access route and comparison of complications or drain dislodgements for TH or TP could not be made. Potential disadvantages of using the TP route are an increased risk of bile peritonitis and colon perforation. The gallbladder could also be more difficult to puncture due to gallbladder mobility. The TP has a decreased risk of bleeding and secondary liver contamination by infected bile. The TH approach decreases the risk of bile leak, portal vessel injury and colon perforation. However, it carries a risk of pneumothorax and bleeding from the liver parenchyma (11, 15). In the current literature there is still debate as to whether which route is preferable. Generally, the radiologists choose the shortest path but the procedure remains interventional radiologist dependent.

Technical problems with cholecystostomies are few. There were 8 drain dislodgements and these patients were managed conservative

Table VI. — Follow-up, complication and technical success rate.

	Calculous	Acalculous	Total
No recurrence	19/87 (21,8%)	17/24 (70,8%)	36/111 (32,4%)
Elective lap. Chol.	34/87 (39,0%)	1/24 (4,1%)	35/111 (31,5%)
Emergency Chol.	17/87 (19,5%)	2/24 (8,3%)	19/111 (17,1%)
Dead in 6 month	17/87 (19,5%)	4/24 (16,6%)	21/111 (18,9%)
Complication	4/87 (4,5%)	2/24 (8,3%)	6/111 (5,4%)
Drain dislodgement	5/87 (5,7%)	3/24 (12,5%)	8/111 (7,2%)
Procedure fail	2/87 (2,2%)	0/24 (0%)	2/111 (1,8%)

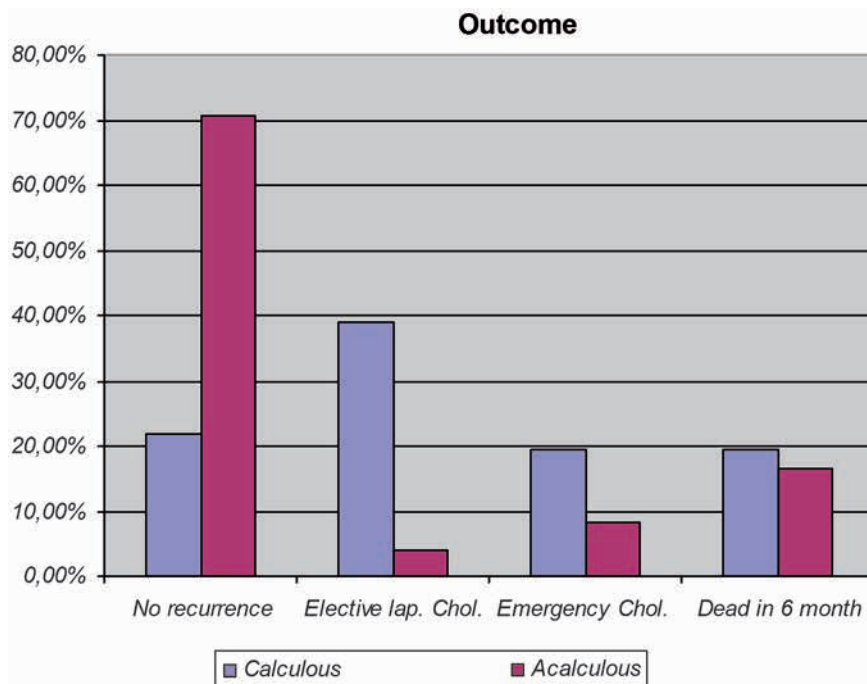


Fig. 2. — Outcome

without complications. The risk of tube dislodgement can be minimized by secure fixation to the skin and use of self-retaining loop catheters.

In our study there were no procedure-related deaths. There were 4 abscesses and 2 fistulas post PC. The overall frequency was very low (5,4%). The patients had non-fatal complications and were treated conservatively. During the follow-up period, 70% of the patients with AAC were treated with PC and had no recurrence and needed no surgery later on. Only 3 interval cholecystectomies have been performed whom 2 for recurrence cholecystitis during long-term follow-up. Therefore, PC may provide definitive treatment in the management of AAC and the majority of patients do not require subsequent cholecystectomy. 58,6% of patients with ACC were operated later on. Thirty-four patients recov-

ered from the acute illness and underwent elective cholecystectomy. Seventeen patients needed an emergency cholecystectomy because of recurrent cholecystitis. PC is an effective treatment in ACC to decompress the inflamed gallbladder but a definitive surgical treatment has to be well-timed planned.

Our data are comparable to results reported by the systematic review conducted by Winbladh et al. (13). Many authors confirm the safety and effectiveness of cholecystectomy for the initial treatment (7, 8, 9). Proper patient selection is important in the ACC group to reduce the risk of recurrence and to avoid urgent cholecystectomy (11, 14, 16). There are many controversies in the current literature. Guidelines with regard to the optimal timing of surgical intervention and management have to be made in treatment of ACC.

Conclusion

In our experience, PC is a safe intervention technique with a high success rate. The complication rate for PC is very low and our results correlated with previous studies. PC is a valuable technique for the management of patients with acute calculous or acalculous cholecystitis. Once the acute symptoms resolve elective cholecystectomy should be followed for patients with gallstones.

References

- Hanbidge A., Buckler P., et al.: Imaging evaluation for acute pain in the right upper quadrant. *RadioGraphics*, 2004, 24: 1117-1135.
- Shapiro M.J., Luchtefeld W.B., Kurzweil S., et al.: Acute acalculous cholecystitis in the critically ill. *Am Surg*, 1994, 60: 335.
- Gore R.M., Yaghami V., Newmark G.M., Berlin J.W., Miller F.H.: Imaging of benign and malignant disease of the gallbladder. *Radiol Clin N Am*, 2002, 40: 1307-1323.
- Garcia-Sancho T., Fernandez de Lis J.A., et al.: Acute emphysematous cholecystitis. Report of twenty cases. *Hepatogastroenterology*, 1999, 46: 2144.
- Morse B.C., Smith J.B., Lawdahi R.B., Roettger R.H.: Management of acute cholecystitis in critically ill patients: contemporary role for cholecystostomy and subsequent cholecystectomy. *Am Surg*, 2010, 76: 708.
- Pessaux P., Regenet N., Tuech J., et al.: Laparoscopic versus open cholecystectomy: a prospective comparative study in elderly with acute cholecystitis. *Surg Laparosc Endosc Percutan Tech*, 2001, 11: 252-255.
- Avrahami R., Badani E., Watemberg S., et al.: The role of percutaneous transhepatic cholecystostomy in the management of acute cholecystitis in high-risk patients. *Int Surg*, 1995, 80: 111-114.
- Byrne F., Suhocki P., Mitchell R.: Percutaneous cholecystostomy in patients with acute cholecystitis: Experience of 45 patients at a US referral center. *J Am Coll Surg*, 2003, 197: 206-211.

9. Joseph T., Unver K., et al.: Percutaneous Cholecystostomy for Acute Cholecystitis: Ten-Year Experience. *JVIR*, 2001, 23: 83-88.e1.
 10. Ito K., Fujita N., Noda Y.: Percutaneous cholecystostomy versus gallbladder aspiration for acute cholecystitis: a prospective randomized controlled trial. *AJR Am J Roentgenol*, 2004, 183: 193.
 11. Basaran O., Yavuzer N., et al.: Ultrasound-guided percutaneous cholecystostomy for acute cholecystitis in critically ill patients: Once center's experience. *Turk J Gastroenterol*, 2005, 16: 134-137.
 12. Shea J., Berlin A., Escarce J.: Revised estimates of diagnostic test sensitivity and specificity in suspected biliary tract disease. *Arch Intern Med*, 1994, 154:2573-2581.
 13. Winbladh A., Gullstrand P., Svanvik J., Sandstrom P.: Systematic review of cholecystostomy as a treatment option in acute cholecystitis. *HPB (Oxford)* 2009, 11: 183-193.
 14. Patel M., Miedema B.W., James M.A., et al.: Percutaneous cholecystostomy is an effective treatment for high-risk patients with acute cholecystitis. *Am Surg*, 2000, 66: 33-37.
 15. Kaufman J.A., Lee M.J.: Gallbladder intervention. In: Kaufman JA, Lee MJ Vascular & interventional radiology: The Requisites. Philadelphia, 2004, pp 588-601.
 16. McGillicuddy E.A., Schuster K.M., Barre K., et al.: Non-operative management of acute cholecystitis in the elderly. *Br J Surg*, 2012, 99: 1254-1261.
-