

TRAUMATIC INTRAPERICARDIAL DIAPHRAGMATIC HERNIATION

E. Schollaert, D. Devos¹

Key-word: Hernia, diaphragmatic

Background: A 61-year-old man was referred to our hospital after a high impact motor vehicle accident. A full body CT scan revealed a cranial subdural hematoma and multiple fractures of the axial and appendicular skeleton (not shown), as well as a retrosternal hematoma. Because of steadily decreasing hemoglobin and hematocrit levels on day 2, a repeat thoraco-abdominal CT scan was performed, but active bleeding was not found. On day 7, sudden desaturation and increased drain output from the nasogastric tube prompted for a repeat thoraco-abdominal CT scan.

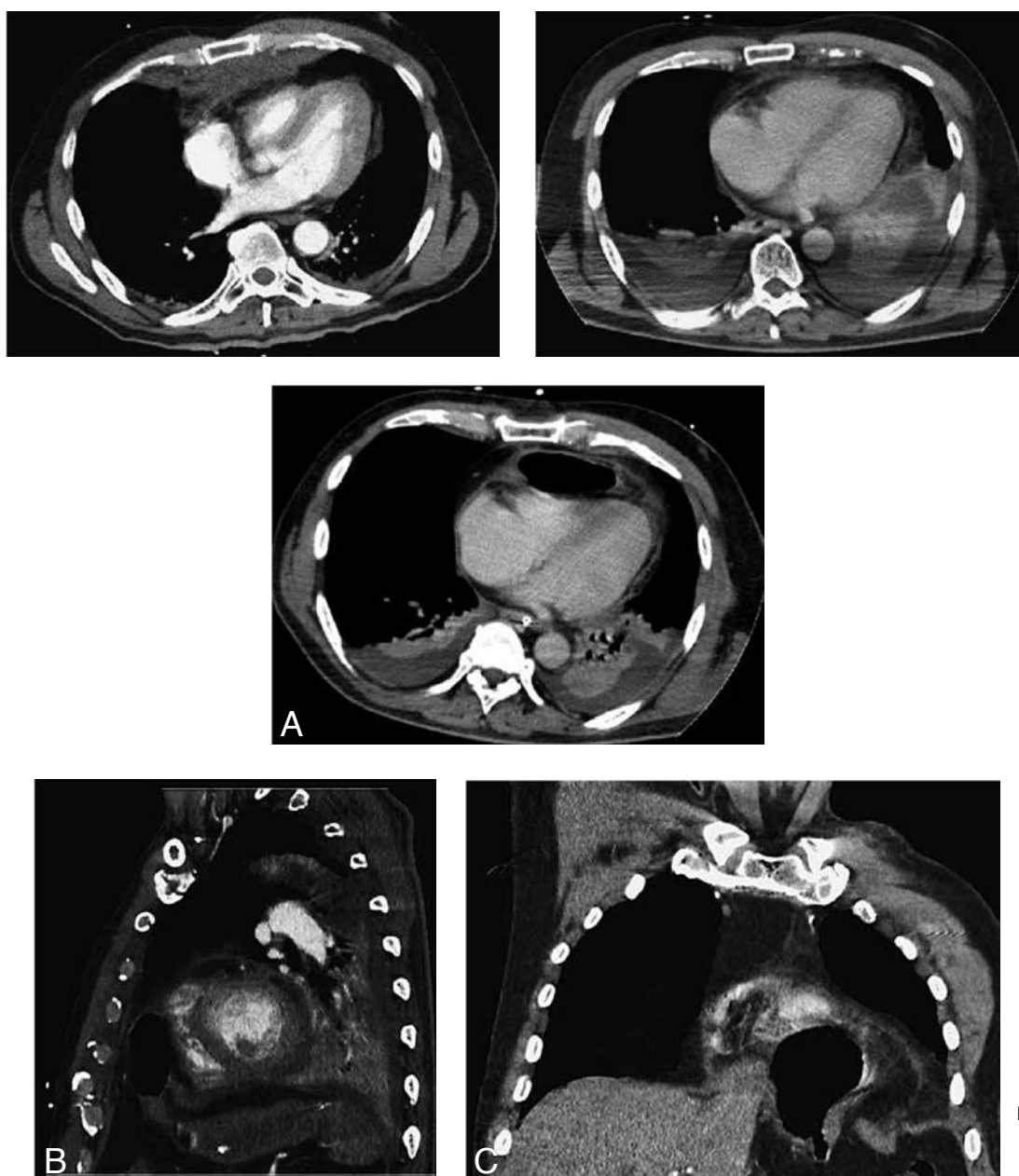


Fig.

1	2
3A	
3B	3C

1. Department of Medical Imaging, University Hospital Ghent, Ghent, Belgium

Work-up

Contrast-enhanced CT scan (day 0) (Fig. 1) shows on axial section at the level of the cardiac ventricles a retrosternal hematoma, originating from a sternal fracture, is delineated from the subepicardial fat at the anterolateral side of the right ventricle. The pericardium seems normal.

On contrast-enhanced CT scan (day 2), axial section at the level of the cardiac ventricles (Fig. 2) the retrosternal hematoma has disappeared almost completely. There is minimal fluid effusion in the pericardium. Bilateral pleural effusions with associated partial compression atelectasis of the lungs are noted.

On contrast-enhanced CT scan (day 7) (Fig. 3), axial section at the level of the cardiac ventricles (A), the anterior pericardial space contains a large air bubble, some fat, and fluid. The right cardiac ventricle is moderately compressed. On the sagittal image at the level of the posterior aortic arch. (B) and the coronal image through the anterior precordial space (C), there is a large gap in the left antero-central part of the diaphragm ("gap sign") with partial herniation ("collar sign") of the stomach and omental fat into the pericardial sac. The liver has not herniated.

Radiological diagnosis

Based on the clinical history of blunt thoraco-abdominal trauma and consecutive CT findings, the diagnosis of *traumatic intrapericardial diaphragmatic herniation* was made. Surgical exploration confirmed a pericardio-diaphragmatic rupture.

Discussion

Traumatic intrapericardial diaphragmatic herniation (IPDH) is a rare entity. While the diaphragm is damaged in 0.8-5% of cases of major thoraco-abdominal trauma, associated IPDH occurs in less than 1% of those cases. Blunt trauma resulting from motor vehicle accidents has emerged as the most common cause.

In blunt thoraco-abdominal trauma, the mechanism leading to diaphragmatic rupture is characterized by a sudden rise in intra-abdominal pressure. This rupture can be located along the right or left

side of the diaphragm, or very rarely in the central tendon. If the rupture extends to the pericardium, abdominal content may herniate directly into the pericardial sac.

Clinical presentation can be asymptomatic, or may include nonspecific cardiorespiratory (hypotension, dyspnea) and/or gastrointestinal (pain, obstruction) symptoms, or a cardiac tamponade which may be fatal.

An abnormal air shadow in the cardiac area on chest radiographs is suggestive of IPDH, but CT is the preferred diagnostic modality in cases of suspected diaphragmatic rupture. Other diagnostic tools such as MRI, gastrointestinal contrast studies, and echocardiography, may lead to this diagnosis.

The time interval between trauma presumed to cause the pericardio-diaphragmatic rupture and the diagnosis can be variable. Because of the lower pressure in the thoracic cavity compared to the abdominal cavity, traumatic defects in the diaphragm usually do not close spontaneously. A small defect can initially go unrecognized, but may slowly or suddenly enlarge and become symptomatic due to progressive herniation.

In our case, there was no evidence of diaphragmatic rupture on the initial scan. Symptoms related to this diaphragmatic rupture appeared only a week after trauma. We conclude that a high index of suspicion is required in all severe thoraco-abdominal trauma cases.

Bibliography

1. Beless D.J., Organ B.C.: Delayed presentation of intrapericardial diaphragmatic hernia, an unusual cause of colon obstruction. *Ann Emerg Med*, 1991, 20: 415-417.
2. Cipe G., Genç V., Uzun C., et al.: Delayed presentation of a traumatic diaphragmatic rupture with intrapericardial herniation. *Hernia*, 2012, 16: 485-488.
3. Nejmeddine A., Mohamed A., Khalil K., et al.: Cardiac tamponade secondary to traumatic intrapericardial diaphragmatic hernia. *J Thorac Cardiovasc Surg*, 2008, 136: 1087-1089.
4. Reina A., Vidana E., Soriano P., et al.: Traumatic intrapericardial diaphragmatic hernia: case report and literature review. *Injury*, 2001, 32: 153-156.