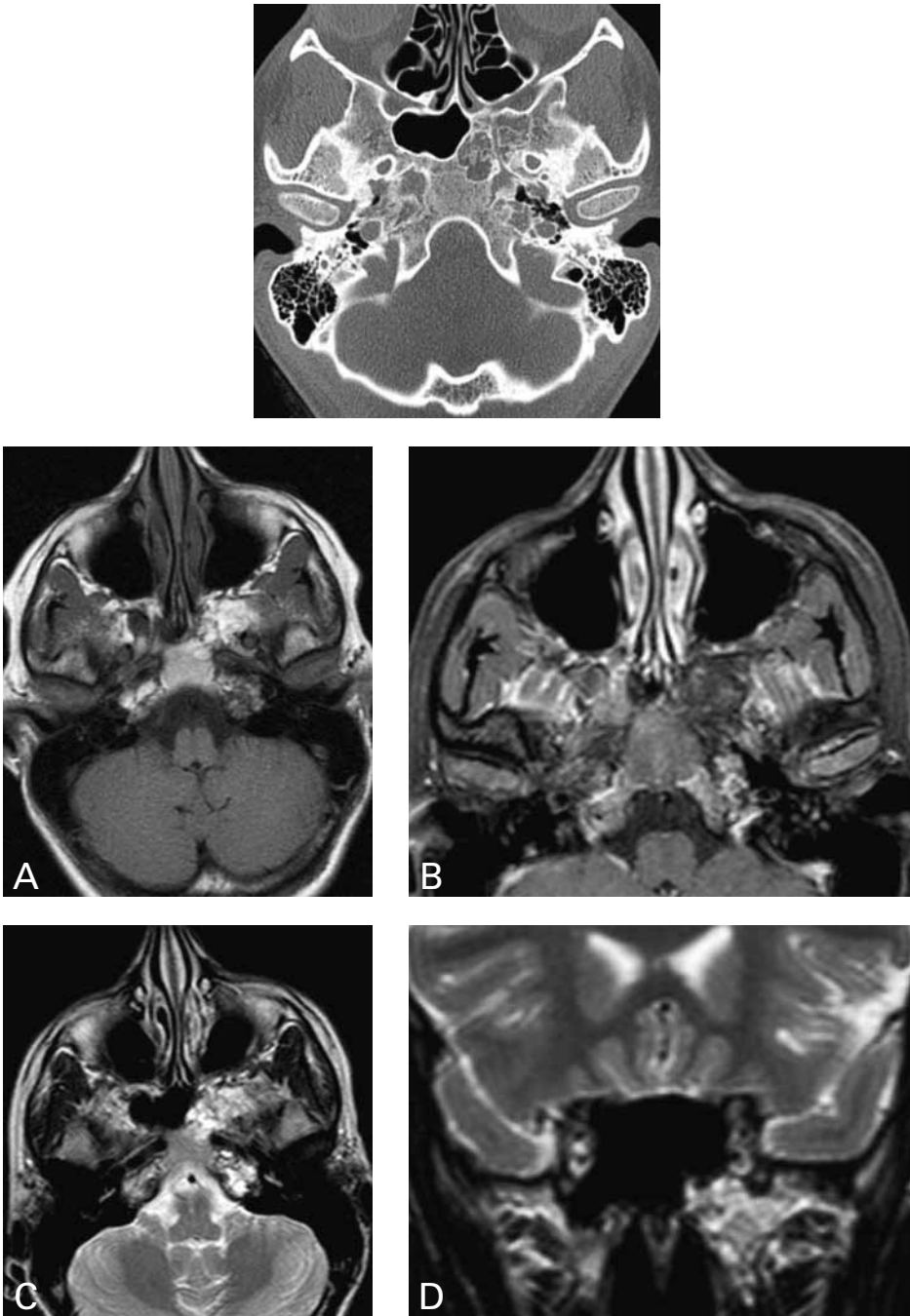


ARRESTED PNEUMATIZATION OF THE SKULL BASE

M.D.F. De Jong, T.A. Fassaert, E.R. Ranschaert¹

Key-word: Skull, base

Background: A 24-year-old woman was referred to a neurologist by her general practitioner, because of complaints of headaches and photophobia with intermittent nausea and vomiting for several years. Physical, neurological and laboratory investigations were unremarkable.



1. Department of Radiology, Jeroen Bosch Hospital, 's Hertogenbosch, The Netherlands

Work-up

Axial CT scan of the skull base (Fig. 1) shows lesion with sclerotic borders and internal curvilinear calcifications, located in sphenoid bone, anterior clinoid process and petrosal apex. Normal position and aspect of the vidian canal and inferior orbital fissure, indicating the absence of mass effect.

MRI of the brain (Fig. 2) shows on axial T1-weighted images (A) a heterogeneous high signal localized in the apex of the left petrosal and sphenoid bone without evidence of mass effect. On axial T1-weighted images with SPIR and following Gd-DOTA administration (B), the lesion shows low signal without enhancement indicating fatty content. Axial T2-weighted images (C) demonstrates heterogeneous high signal of the lesion indicating partially cystic components. Coronal T2-weighted images (D) demonstrates heterogeneous high signal of the lesion indicating partially cystic components without evidence of mass effect.

Radiological diagnosis

The presence of internal fat and curvilinear calcifications without mass effect or erosive components in a lesion often accompanied with microcystic components, located in the sphenoid bone, is characteristic for *arrested pneumatization of the skull base*.

Discussion

The normal process of pneumatization of the skull base and paranasal sinus starts at the age of 4 months and develops through young adulthood. Red bone marrow is being replaced by fatty marrow prior to pneumatization of the paranasal

sinus, including the sphenoid bone by mechanisms that remain largely unclear. This bone marrow conversion precedes the invasion of epithelial cells which becomes respiratory mucosa in the aerated sinus. When one of the steps described above is halted, no or only reduced pneumatization will occur.

Imaging consists of CT and MR studies involving the skull base. Characteristic features are a non-expansile lesion with internal curvilinear calcifications with sclerotic margins on CT scans.

Hallmark of MR imaging is the presence of internal fat representing the persistent fatty marrow and microcystic components, without evidence of mass effect.

The nonexpansile nature of the lesion is best evaluated at the fissura orbitalis inferior and vidian canal, which are not displaced nor disrupted.

Differential diagnosis includes fibrous dysplasia, ossifying fibroma, chondrosarcoma, osteomyelitis, chordoma

and metastasis. All of the mentioned conditions lack the presence of internal fat or show signs of mass effect.

Bibliography

1. Speath J., Krugelstein U., Schlondorff G.: The paranasal sinuses in CT-imaging: development from birth to age 25. *Int J Pediatr Otorhinolaryngol*, 1997, 39: 25-40.
2. Welker K.M., et al.: Arrested pneumatization of the skull base: imaging characteristics. *AJR*, 2008, 190: 1691-1696.
3. Yometsu K., Watanabe M., Nakamura T.: Age-related expansion and reduction in aeration of the sphenoid sinus: volume assessment by helical CT scanning. *Am J Neuroradiol*, 2000, 21: 179-182.